

An Automatic Detection and Assessment of Diabetic Macular Edema Along With Fovea Detection from Color Retinal Images

S.Fowjiya^{1#}, Dr.M.karnan^{2@}, Mr.R.Sivakumar^{3*}
Department of CSE, Tamilnadu College of Engineering, Coimbatore,
Tamilnadu,India.

1[#] Student 2[@] Professor 3^{*} Research scholar

Abstract: Diabetic macular edema (DME) is an advanced symptom of diabetic retinopathy which lead to vision loss. Here a methodology comprises of two stages is proposed. First stage is detecting of DME and the next stage is assessing the severity of DME. DME detection is carried out via a supervised learning approach. A technique called feature extraction is introduced here to capture the global characteristics of fundus images. It will discriminate the normal images from DME images. A rotational asymmetry metric is used to assess disease severity by examining macular region symmetry. Along with this fovea detection is also performed to make detecting process further easier.

Keywords- Diabetic macular edema, hard exudates, rotational symmetry, diabetic retinopathy.

I. INTRODUCTION

Diabetic macular edema is one of the symptom which can lead to vision loss from diabetic retinopathy. An increase in extracellular fluid within the retina distorting the retinal architecture leads to decreased vision. Because of the breakdown of the barriers within the retinal blood vessels the fluid will surround the retina, exactly at the epithelium pigment. DME can be detected directly or indirectly. Direct ways are using stereoscopy. Indirect method is by detecting the presence of hard exudates (HE) in the retina. HE are formed due to secretion of plasma from capillaries and could lead to retinal swelling. Detecting the presence of hard exudates (HE) in different areas of retina is a standard method to assess DME from color fundus images.

Manual assessment will not practically employed in large-scale screening area, particularly in developing countries. This

is only either due to the scarcity of skilled manpower. The another reason is unavailability of high end imaging equipment at the needed point of care. Telescreening using permanent units and mobile units are the solutions which is used to enable screening of retinal disorders in remote areas. To reduce the manual assessment, load of experts and time, to the cases who need immediate attention, an automatic solution for assessment of DME from color fundus images, is created which will be a value addition to the existing infrastructure of DR screening.

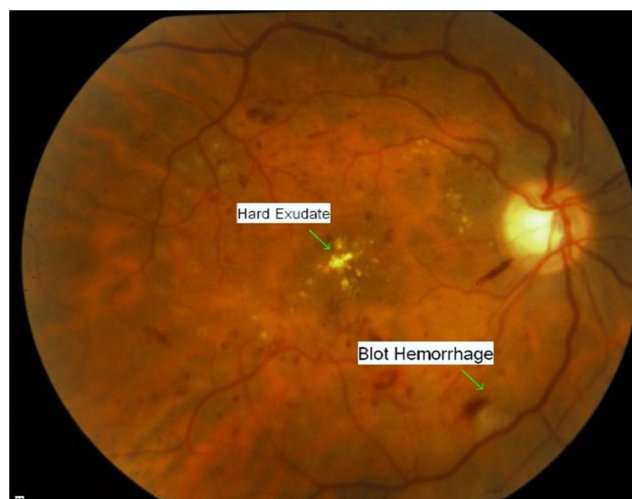


Fig.1. Example of Diabetic Macular edema with hard exudates

In order to develop a solution for automatic DME assessment, first a decision module is required to validate the presence or absence of HE in a given color fundus image. Once their presence is confirmed, assesment of the macular region for measuring the risk should be exhibited in second module. Therefore, a two-stage methodology for detection and assesment of DME is presented. The next section provides an earlier work carried out for detecting the presence of HE followed by an proposed methodology outline.

II. BACKGROUND AND PAST WORK

Detection of DME using indirect method is still considered a reliable method in DR screening. Detecting DME is done indirectly by detecting the presence of HE in images. Hard exudates can be present in conditions that are associated with chronic vascular leakage.

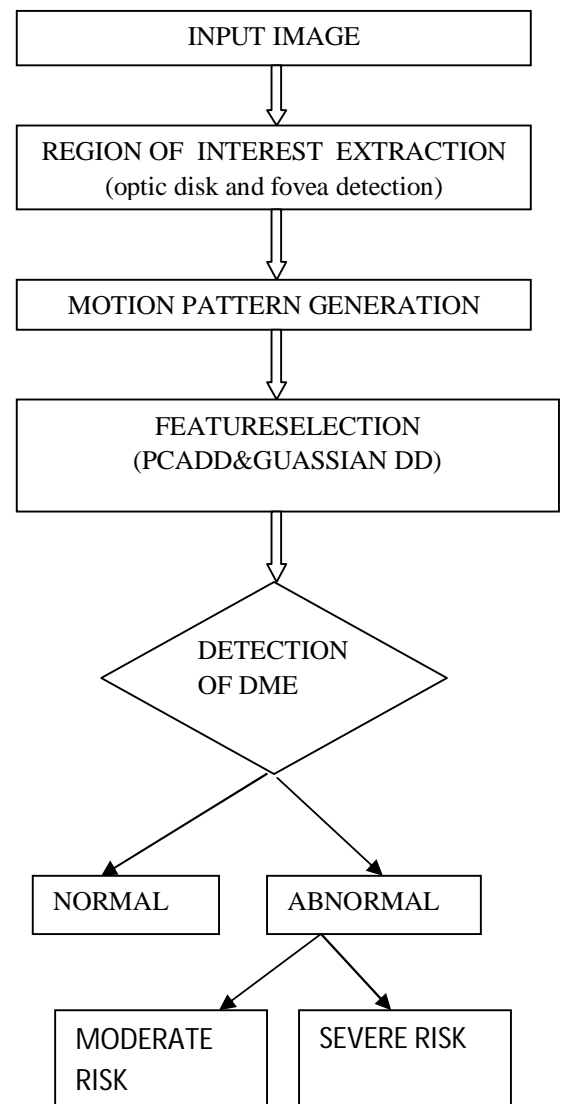
Detecting DME is also done indirectly by detecting the presence of HE in images. Automated solutions following this approach can be categorized as: 1) local schemes that perform localization of HE or HE clusters. 2) global schemes for detecting the presence/absence of HE in images.

The purpose of the local schemes is to successfully segment and localize the HE clusters with higher degree of accuracy which is used to perform the assesment of DME. As a result, several normal pixels are also detected as candidates in the given images. This affects the overall specificity of the system at image level HE detection. The purpose of local schemes is to detect maximum number of HE, the purpose of global schemes is to ensure that at least the brightest pixels corresponding to HE in the image Background suppression is an approach used for finding HE candidates by using the techniques background estimation including median filtering ,morphological operations and clustering. These approaches are sensitive to illumination changes that arise due to imaging conditions .The well-defined edges of HE also been used as a clue to identify candidate pixels. However, small or faint HE detection is difficult and need additional rules are used to handle them. Edge detection yields noisy results and hence preprocessing and postprocessing steps are required to reduce the large number of false candidates.

Visual word/group using a dictionary have also been used to represent color fundus images to help classify the image as normal or abnormal [2], [3].

The visual word-based approach is robust to illumination changes across images. This is achieved by using a large number of clusters[2], [3]. The sensitivity of SIFT to local intensity variations results in increasing the computational complexity of the overall detection. Using the global characteristics of an image while retaining the sensitivity to small HE. Here the transformation of the given image to an intermediate representation called motion pattern is done, that spatially enhances the HE presence regardless of their size along with fovea detection.

III. FLOW DIAGRAM OF DETECTION AND ASSESSMENT PROCESS



IV. PROPOSED METHOD

HE will be looking like a clusters of bright, high contrast lesions and are well localized. The macula is a dark structure present at the center of the retina. If there is no any HE , a rotational symmetry(rough) is seen about the macula in the circular region which is roughly twice the diameter of the optic disc. The detection process of DME can be done as follows,The image taken for evaluation is first assumed to be normal. Any deviation from normal characteristics is taken to be indicative of abnormality. For every abnormal image the severity of DME is assessed by determining the location of HE relative to the macula with fovea detection.

A.Extraction of region of interest

The images acquired for DME detection usually focus around the macular region. The best fit circle within the image mask with macula at the center, for a given image is found. The green channel which has been extracted forms the input for all subsequent processing.The center of macula is automatically detected using and avoiding the search to a central region of the image since the acquired images for DME detection are macula-centric. Since the OD shares a brightness characteristic similar to HE, it is also automatically detected and masked.

B.Fovea Detection

Fovea can be detected easily at the region where the blood vessels does not occur.Fovea is a centalised region where exact region of macula is present.To find the region of macula it is necessary to find out the fovea region,where the bloodvessels doesnt pass through it.once the optic disk is found it is easy to find the foveal region which is present in the distance of one diameter.

C.Motion Patterns Generation

The creation of a motion pattern is motivated by the effect of motion on biological/computer visual system. Here motion is induced in a given image to generate a sequence of images. These are combined by applying a function to coalesce the intensities at each sensor location to give rise to a motion pattern. A motion pattern for is derived as follows,Let the given ROI be denoted as Imp.

$$Imp(r)=f(G_N(I(r))) \tag{1}$$

where r denotes a pixel location, G_N is a transformation representing the induced motion which is assumed to be rigid. Practically speaking, G_N generates N transformed images which are combined using to f coalesce the sampled intensities at each pixel location (1). Here, G_N(I) is expressed as follows:

$$G_N(I)=(R\Theta_n(I)) \tag{2}$$

where is a rotation matrix. This is a set of rotated versions of the given and the total number of rotated images.The transformation function is applied to generate a sequence of images which are rotated versions.The spatial extent of smearing of intensities depends on the maximum rotation whereas the sampling rate at each location is directly related to the size of each rotation step. the choice of function should ideally

- 1) enhance the HE by increasing the extent of the smear caused by it in the motion pattern
- 2) increase the homogeneity of retinal background. Accordingly, two functions namely Mean and Maximum were considered.

Two functions are described,

$$1.MEAN = IMP(r) = 1/N \sum (R\Theta_n I(r)). \tag{3}$$

$$2.MAX = \max (R\Theta_n I(r)). \tag{4}$$

Mean tries to achieve the averaging effect observed in motion blur, Maximum tries to exploit the fact that HE usually appear brighter than any other structures in the background at the same radial distance.

D.FeatureSelection

The motion pattern generated by inducing motion results in the smearing of lesions.To effectively describe this motion pattern, a descriptor is used to derive from the Radon space.

$$P\hat{a}(r)=\int\int f(x,y)\delta(r-x\cos\phi-y\sin\phi)dx dy. \tag{5}$$

E. Abnormality Detection—Learning Normal Class

Learning normal cases is achieved using **single class classification**. A classification boundary is formed in the feature space around the subspace. If a new image, when transformed to this feature space, lies within this boundary, then it is classified as normal and abnormal otherwise.

Two simple single class classifiers are considered in this work,

*Gaussian data description (Gaussian DD) and

* Principal component analysis data description (PCA DD).

Gaussian DD

The normal class is modeled as a Gaussian distribution. The model parameters, namely, the mean and the covariance are computed for the training set made of normal cases. Classification of a new case is based on the Mahalanobis distance between the new case and the normal subspace which is computed as

$$D(g(I_{mp})) = \{ (g(I_{mp}) - \mu)^T \Sigma^{-1} (g(I_{mp}) - \mu) \} \quad 6$$

PCA DD

A linear subspace is defined for the normal cases. The eigenvectors corresponding to the covariance matrix of the training set is used to describe the subspace. The feature vector $(g(I_{mp}))$ for a new case is projected to this subspace and again reconstructed $(g(I_{mp})_{proj})$. The new case is classified to be normal based on a reconstruction error defined as

$$e(g(I_{mp})) = \|(g(I_{mp}) - (g(I_{mp})_{proj})\|_2 \quad 7$$

For both the above single class classifiers, the classification between normal and abnormal images is performed using an empirical value which determine threshold on and for Gaussian DD and PCA DD classifiers, respectively. Thus the methodology for determining if a given image is normal or abnormal is done. Next, a solution for further subclassifying an abnormal image according to the severity of DME is presented.

F. Determining the Severity of Macular Edema

The macular region which is the circular ROI within 1 optic disc diameter from the center, is key of interest. The macula in a normal image is relatively darker than other regions in the fundus image and is characterized by (rough) rotational symmetry. This information is used to establish the risk of exhibiting edema:

Moderate case-if macula provides a good degree of symmetry

Severe case-if macula establish asymmetrical property.

A method to detect severity of edema based on rotation symmetry has also been used earlier where the symmetry of larger ROI centered on the macula is considered. A slightly different approach is used by considering the symmetry of only the macular region. Removal of blood vessels is not required here, as visibly large vasculature is usually not observed within macula in color fundus image. A symmetry measure is defined as the second norm of the distance between the histograms of diametrically opposite pair of patches $(p(\theta_i))$ and $(p(\theta_i + \pi))$.

A threshold on the symmetry measure is used for assessing the degree of abnormality of an image as moderate or severe risk of DME. Let H_{max} and H_{min} be the maximum and minimum symmetry values for normal images in the training set used for abnormality detection. Then the severity of a given abnormal image is determined by comparing the symmetry measure of this image against a threshold as follows

$$Severity(I_a) = \begin{cases} \text{moderate} & \text{if } H(I_a) \leq T \\ \text{severe} & \text{otherwise} \end{cases} \quad 8$$

It is desirable to set the threshold to be a percentage of the maximum symmetry value for normal images. Hence, the threshold is selected as

$$T = P(H_{max} - H_{min}) + H_{min} \quad 9$$

This definition for permits the value of to be in [0–1]. It is advisable to select a low value to achieve highest classification accuracy for the severe class of DME images as they require immediate medical attention.

V. CONCLUSION

A Novel and hierarchical approach is provided here to classify the given fundus image as normal or abnormal. A rotational asymmetry measure is used to assess the severity of risk of DME. The novel representation captures the global image characteristics. Such global features have not been used successfully earlier for HE detection. This methodology enhances the existing DR screening infrastructure by helping automate the detection and assessment of DME.

REFERENCES

- [1] LGiancardo, F. Meriaudeau, T. Karnowski, K. Tobin, E. Grisan, P. Favaro, A. Ruggieri, and E. Chaum, "Textureless macula swelling detection with multiple retinal fundus images," *IEEE Trans. Biomed. Eng.*, vol. 58, no. 3, pp. 795–799, Mar. 2011.
- [2] A. Rocha, T. Carvalho, S. Goldenstein, and J. Wainer, Points of interest and visual dictionary for retina pathology detection Inst. Comput., Univ. Campinas, Tech. Rep. IC-11-07, Mar. 2011.
- [3] C. Agurto, V. Murray, E. Barriga, S. Murillo, M. Pattichis, H. Davis, S. Russell, M. Abramoff, and P. Soliz, "Multiscale am-fm methods for diabetic retinopathy lesion detection," *IEEE Trans. Med. Imag.*, vol. 29, no. 2, pp. 502–512, Feb. 2010
- [4] Automatic Assessment of Macular Edema From Color Retinal Images K. Sai Deepak* and Jayanthi Sivaswamy
- [5] C. P. Wilkinson, F. L. Ferris, R. E. Klein, P. P. Lee, C. D. Agardh, M. Davis, D. Dills, A. Kampik, R. Pararajasegaram, and J. T. Verdager, "Proposed international clinical diabetic retinopathy and diabetic macular edema disease severity scales," *Am. Acad. Ophthalmol.*, vol. 110, no. 9, pp. 1677–1682, Sep. 2003.
- [6] R. F. N. Silberman, K. Ahlrich, and L. Subramanian, "Case for automated detection of diabetic retinopathy," *Proc. AAAI Artif. Intell. Development (AI-D'10)*, pp. 85–90, Mar. 2010.
- [7] M. Verma, R. Raman, and R. E. Mohan, "Application of tele ophthalmology in remote diagnosis and management of adnexal and orbital diseases," *Indian J. Ophthalmol.*, vol. 57, no. 5, pp. 381–384, Jul. 2009.
- [8] M. D. Abramoff, M. Niemeijer, M. S. Suttorp-Schulten, M. A. Viergever, S. R. Russell, and B. van Ginneken, "Evaluation of a system for automatic detection of diabetic retinopathy from color fundus photographs in a large population of patients with diabetes," *J. Diabetes Care*, vol. 31, no. 2, pp. 193–198, Nov. 2007.
- [9] S. Philip, A. Fleming, K. Goatman, S. Fonseca, P. McNamee, G. Scotland, G. Prescott, P. F. Sharp, and J. Olson, "The efficacy of automated disease/no disease grading for diabetic retinopathy in a systematic screening programme," *Br. J. Ophthalmol.*, vol. 91, no. 11, pp. 1512–7, Nov. 2007.
- [10] H. Jaafar, A. Nandi, and W. Al-Nuaimy, "Detection of exudates in retinal images using a pure splitting technique," in *Proc. Annu. Int. Conf. IEEE Eng. Med. Biol. Soc. (EMBC)*, Aug. 2010, pp. 6745–6748.
- [11] P. C. Siddalingaswamy and K. G. Prabhu, "Automatic grading of diabetic maculopathy severity levels," in *Int. Conf. Syst. Med. Biol. (ICSMB)*, Dec. 2010, pp. 331–334.
- [12] C. I. Sanchez, M. Garca, A. Mayo, M. I. Lopez, and R. Hornero, "Retinal image analysis based on mixture models to detect hard exudates," *Med. Image Anal.*, vol. 13, no. 4, pp. 650–658, Aug. 2009.